

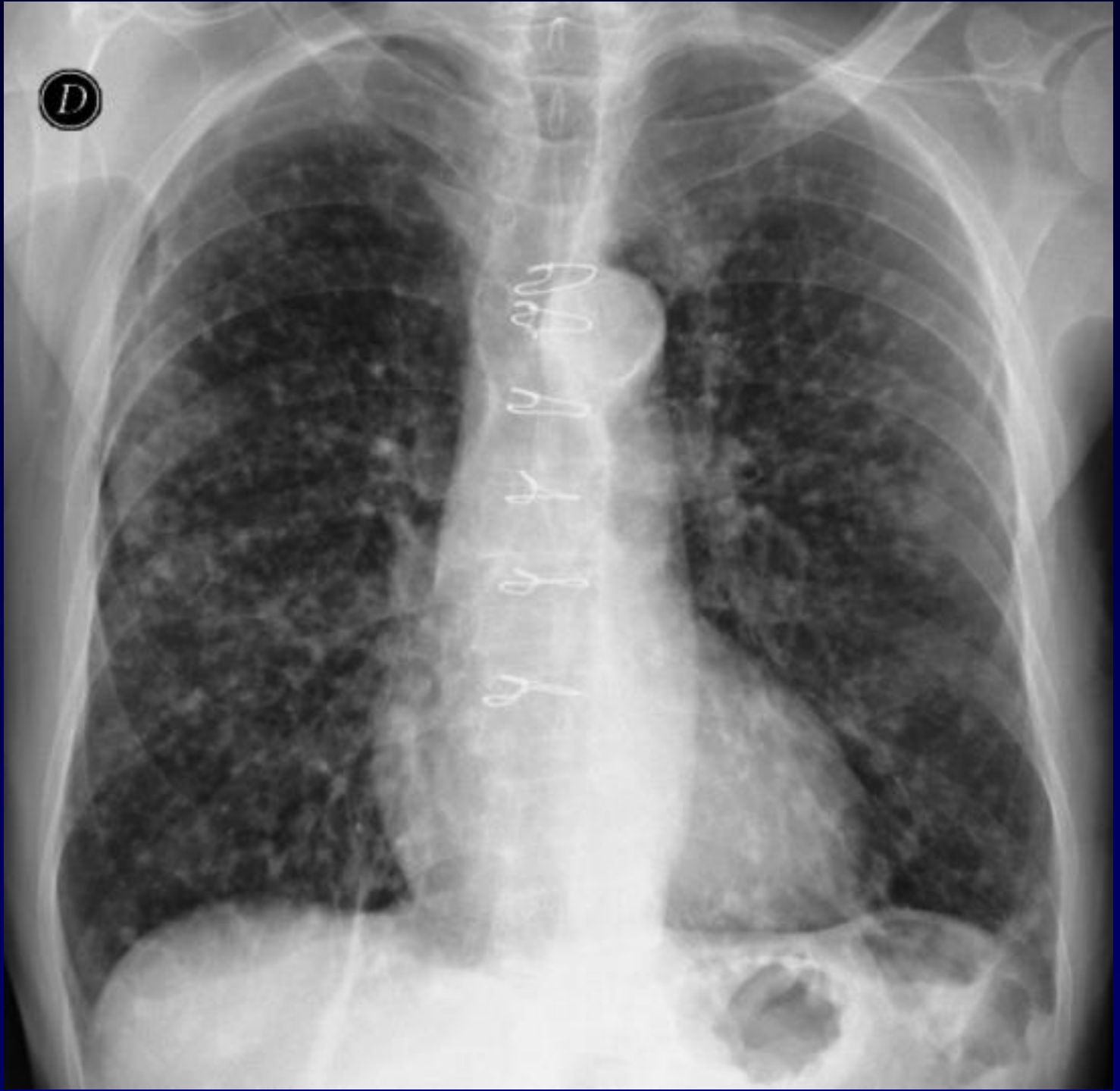
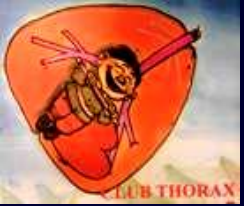
A Khalil – MF Carette

Homme de 80 ans

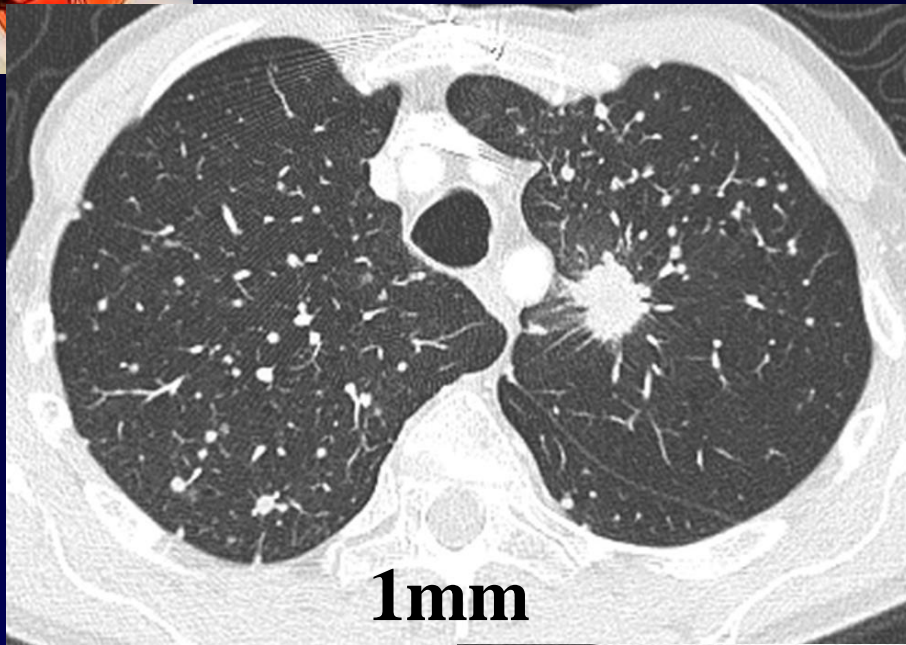
Altération de l'état général

Radiographie thoracique de face

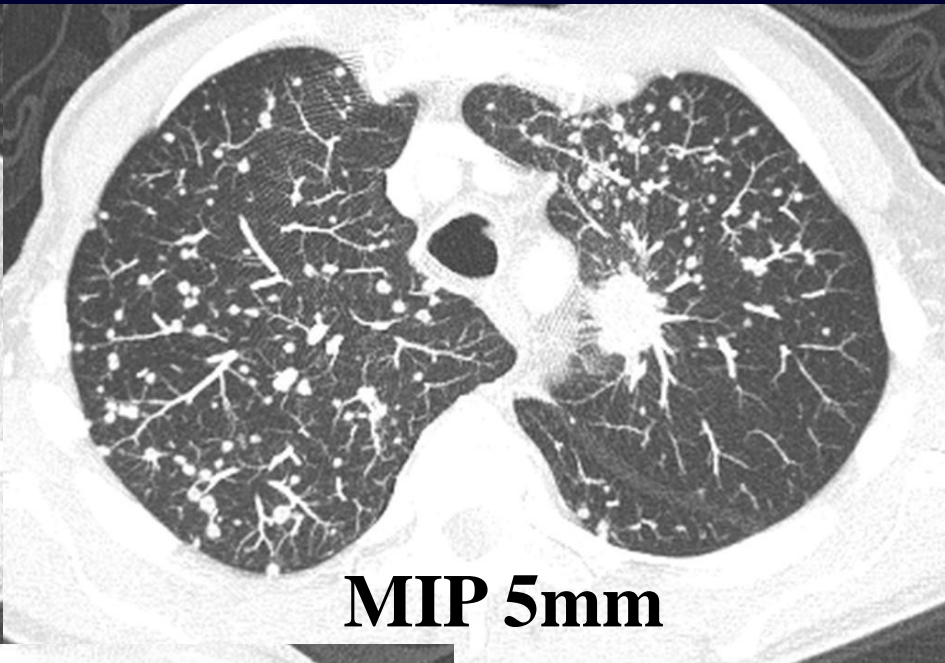




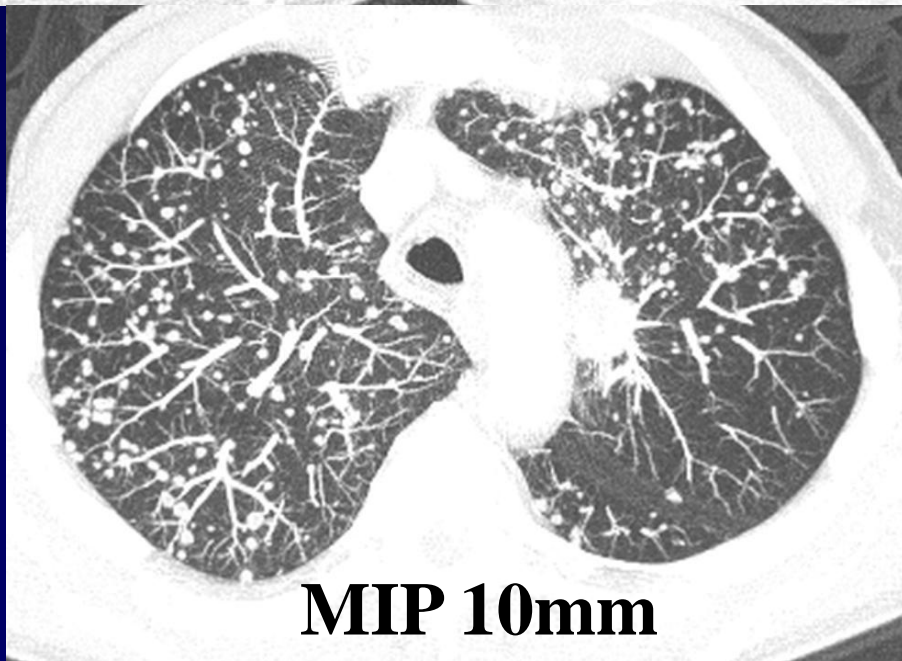
Diagnostic ?



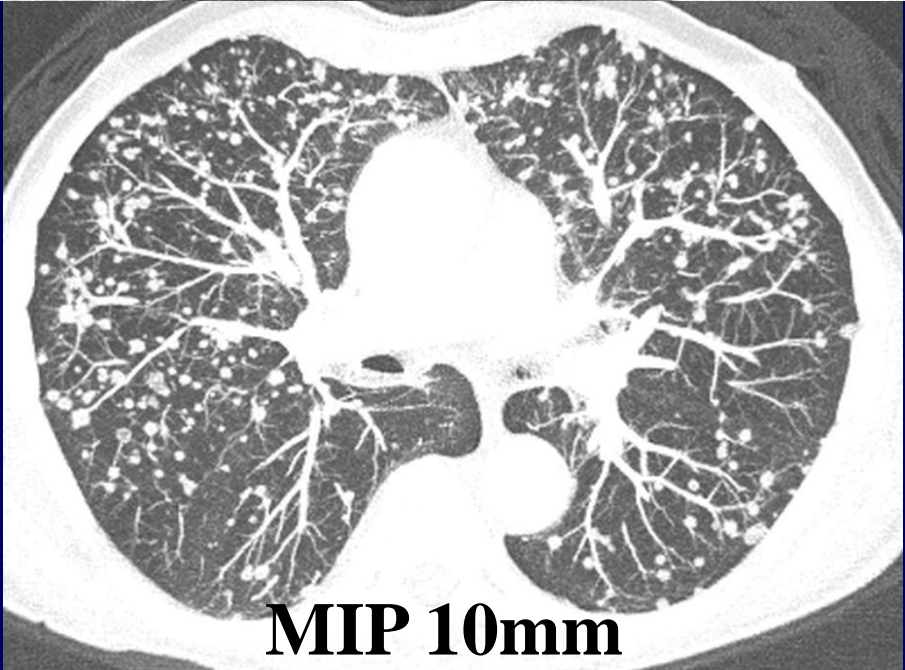
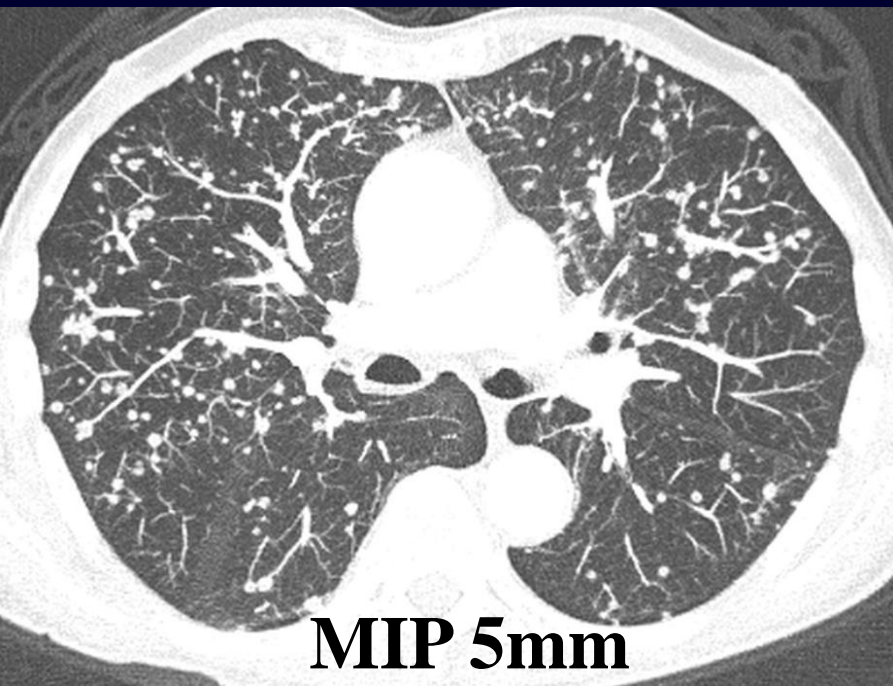
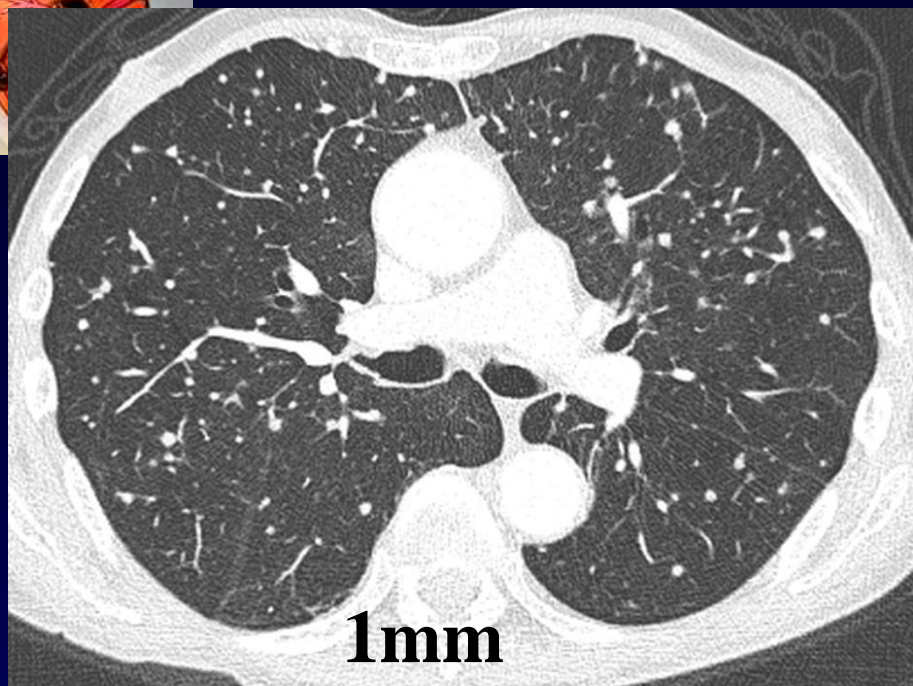
1mm

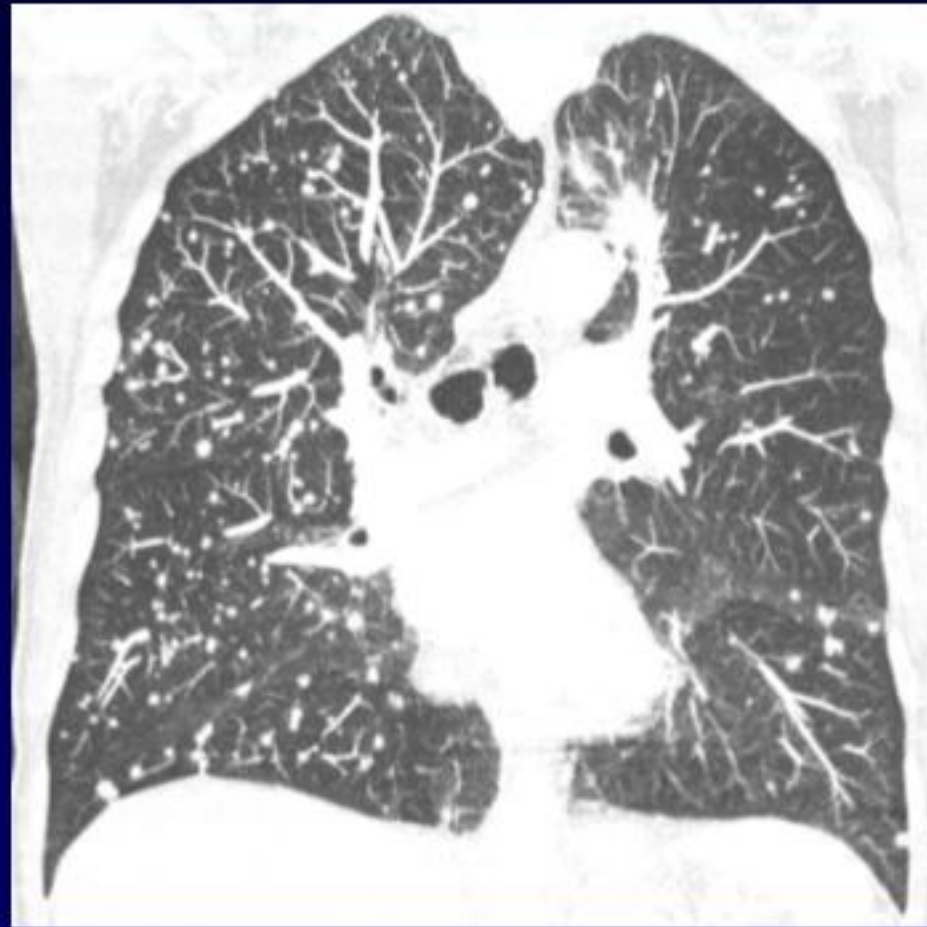
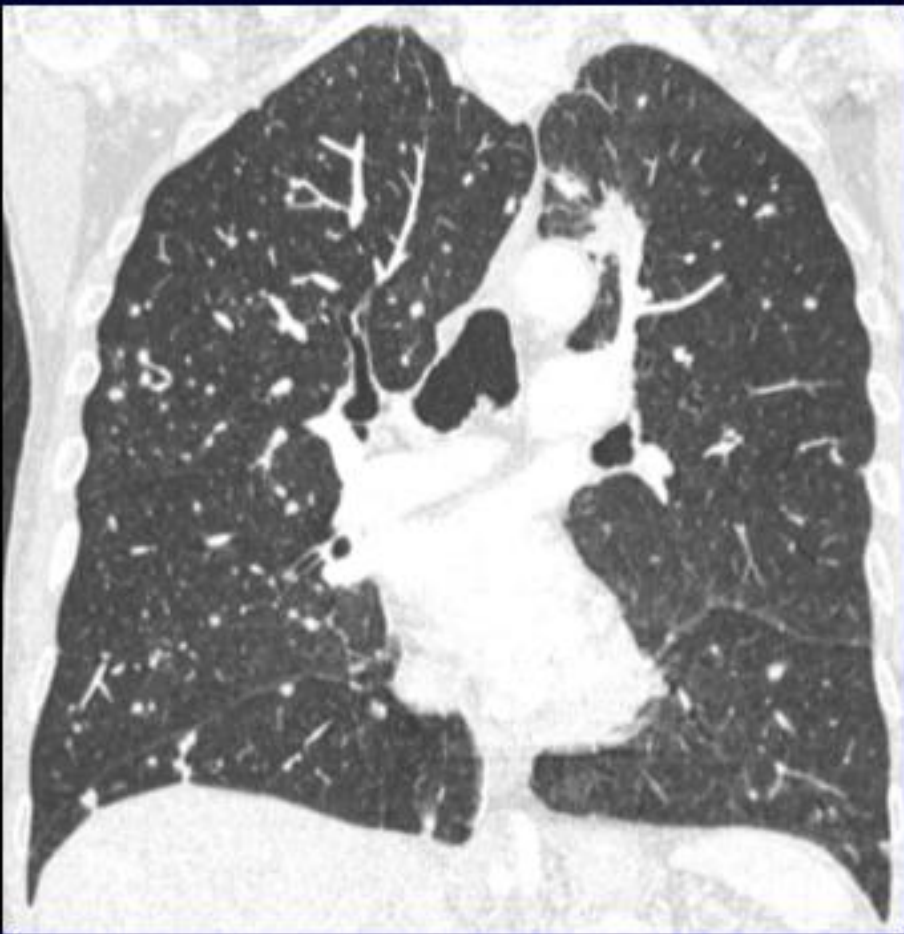
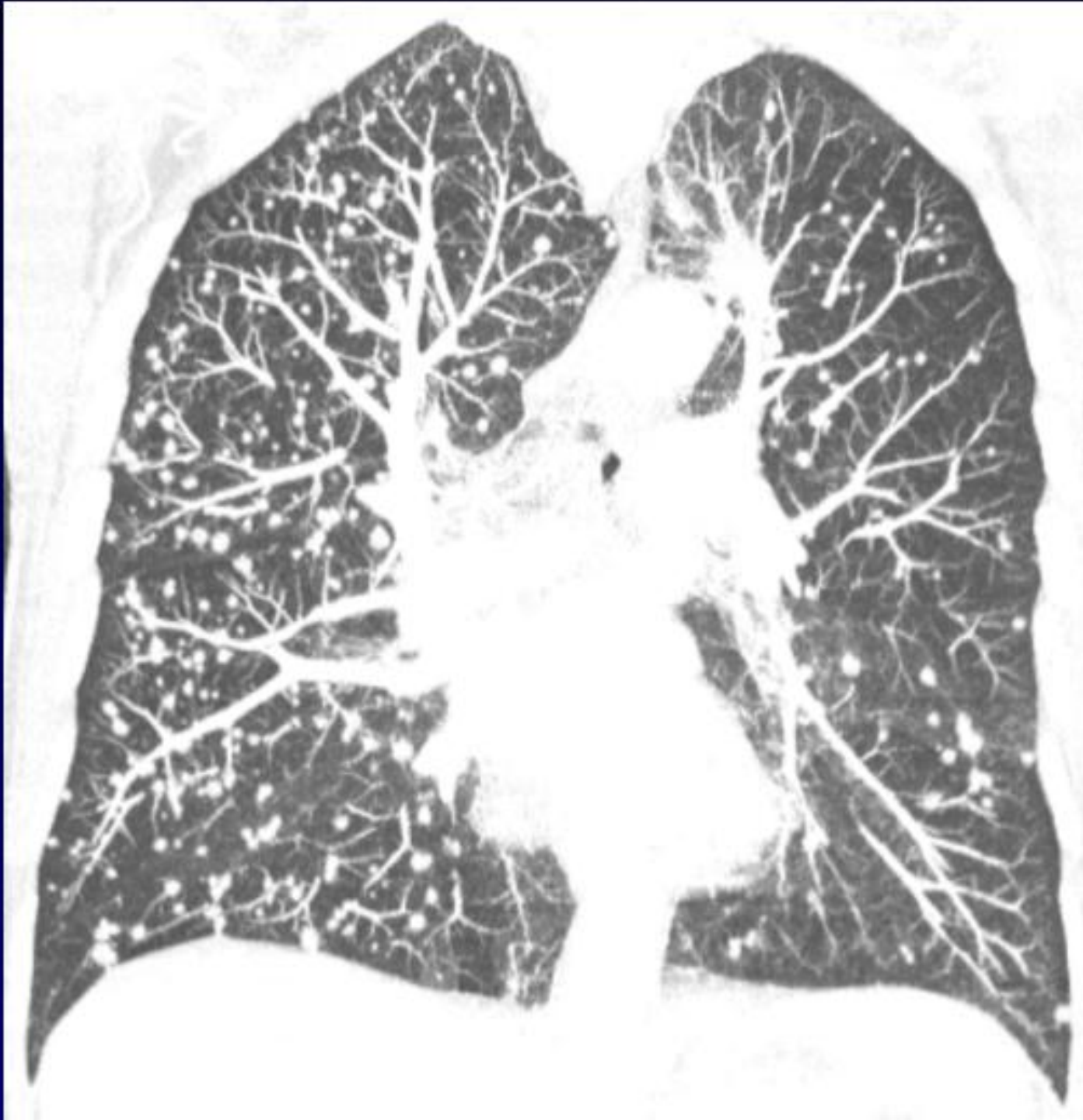MIP 5mm

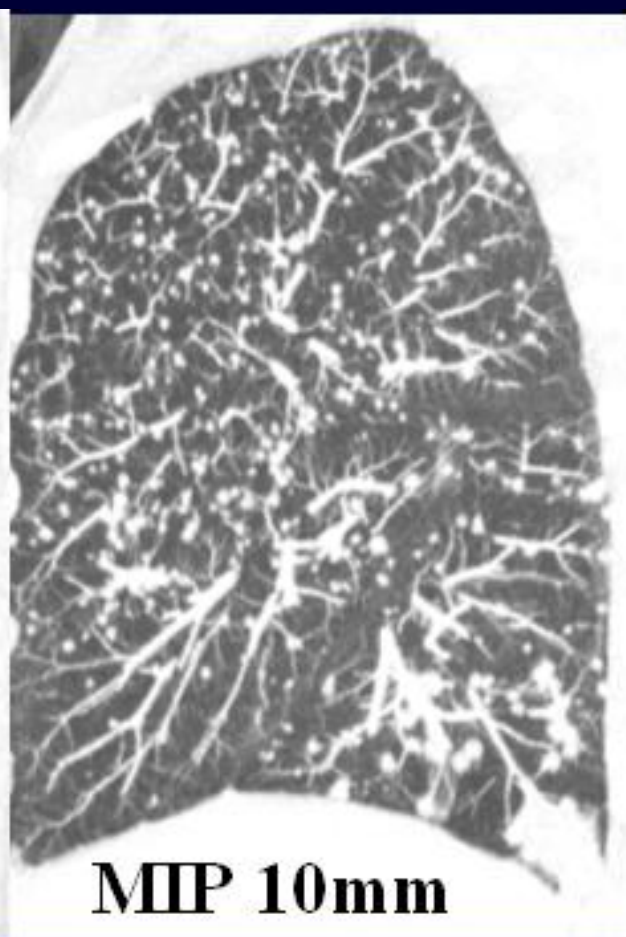
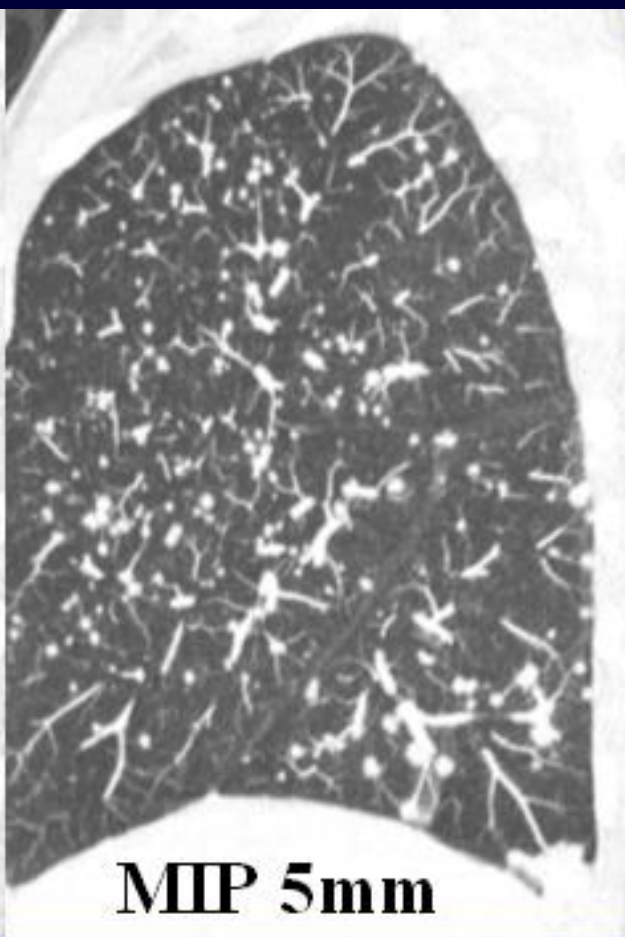
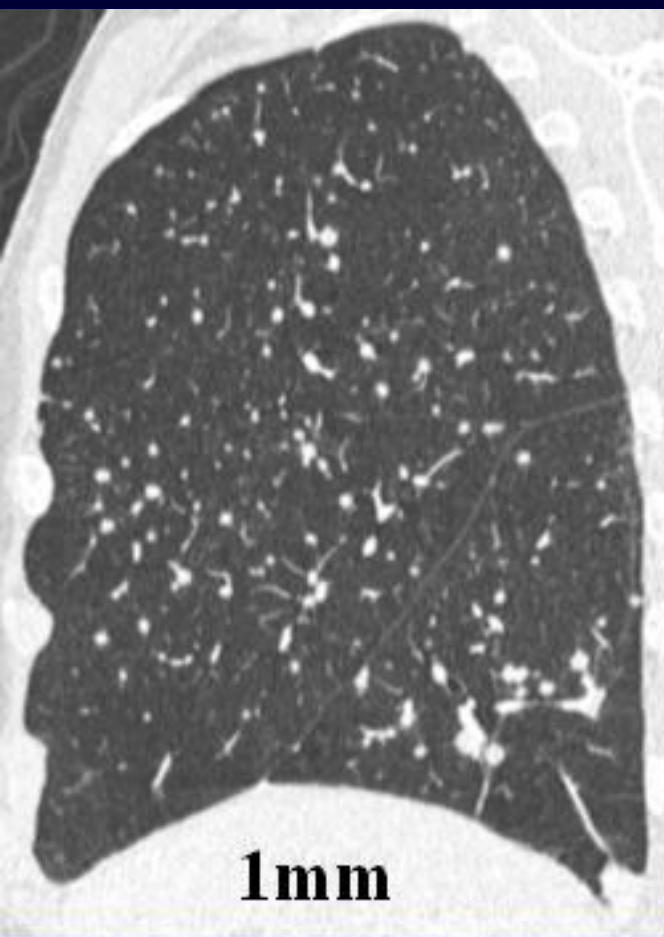


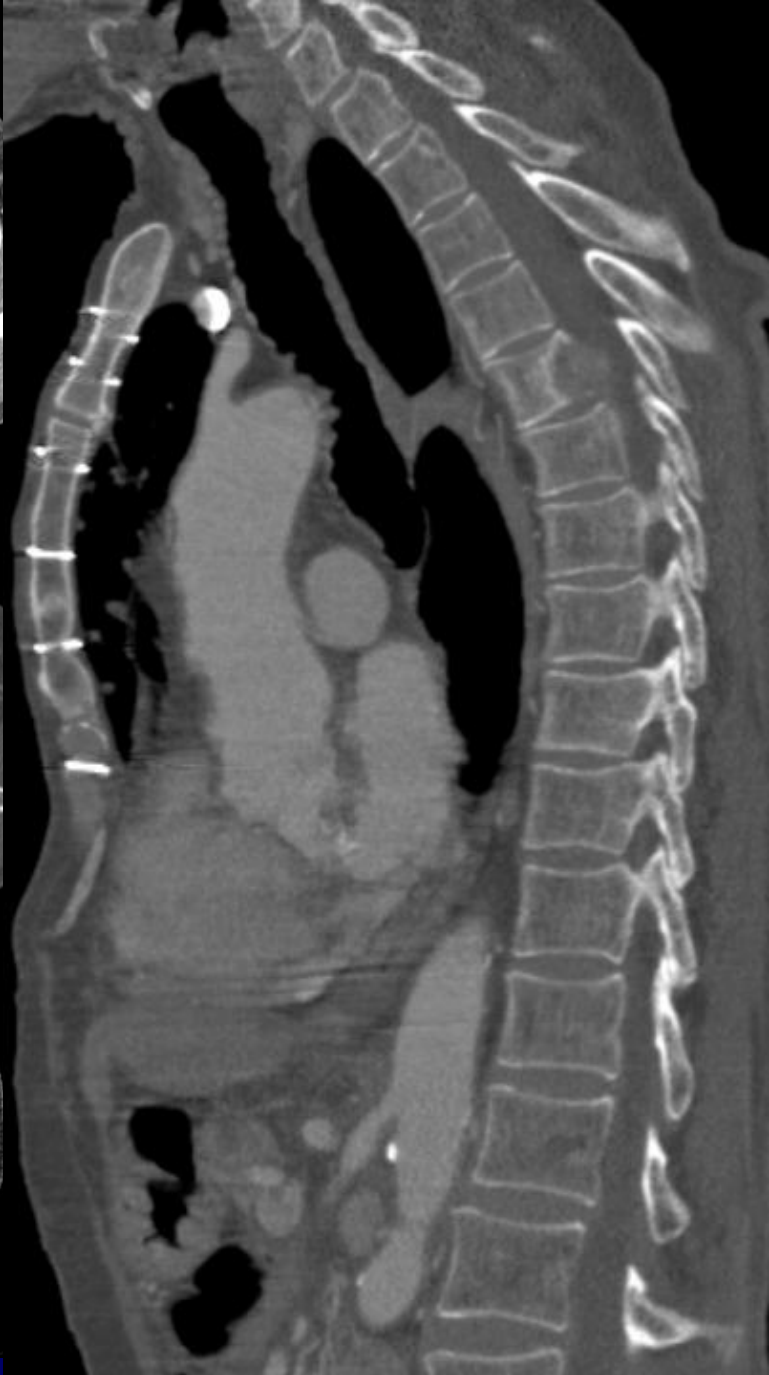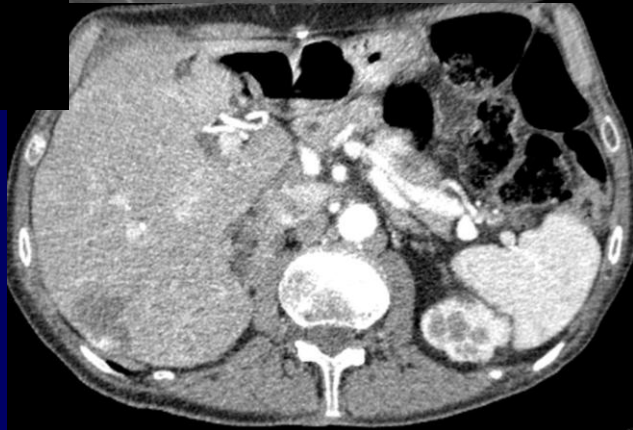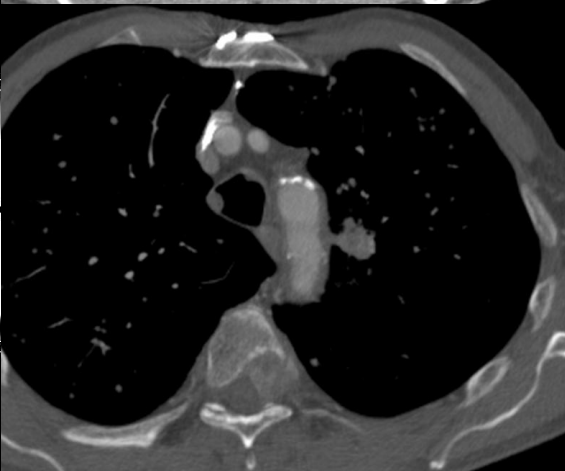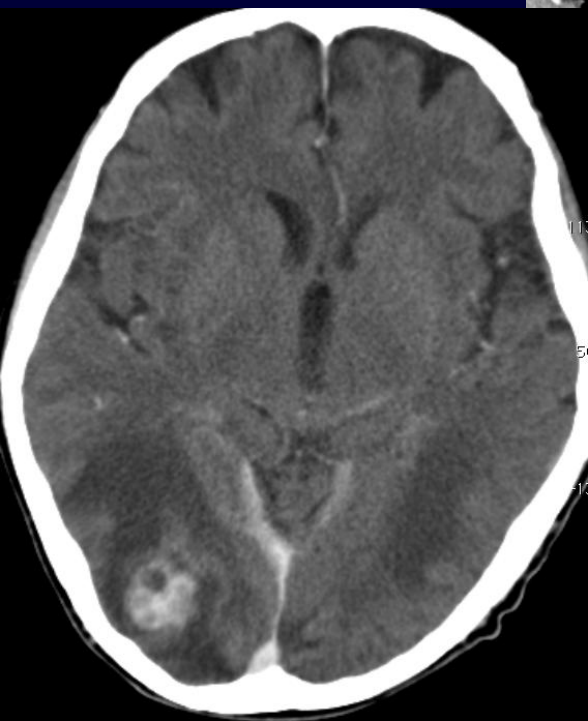
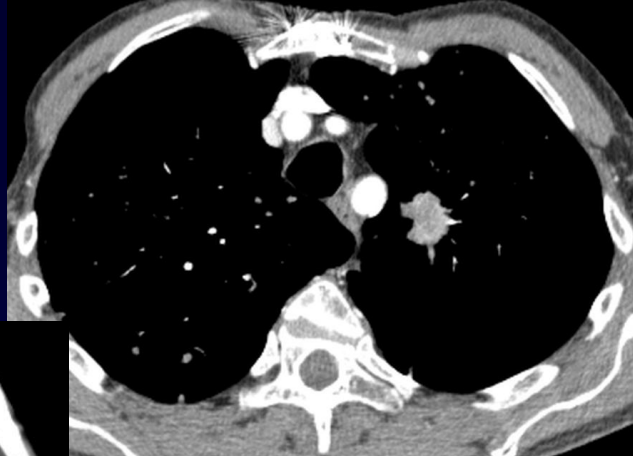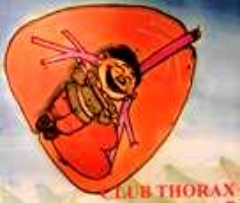MIP 10mm





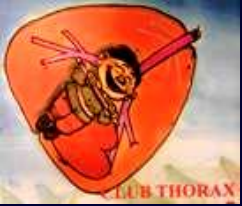







Diagnostic ?



Diagnostic

**Cancer bronchique avec métastases pulmonaires,
surrénalienne, cérébrale et vertébrale.**

Histologie: Adénocarcinome